

# Disseminated peritoneal leiomyomatosis: A case report and review of current events in the media and the literature

P F Kruger, MB ChB, FRCS (Canada) (O&G); P Lee, MDCM, FRCS (Canada), FACOG

Sunnybrook Health Sciences Centre, Department of Obstetrics and Gynaecology, University of Toronto, Canada

Corresponding author: P F Kruger (pkruger@ualberta.ca)

Disseminated peritoneal leiomyomatosis (DPL) is a rare, mostly benign clinical condition where multiple smooth-muscle nodules or growths of various sizes of uterine origin implant on the abdominal, pelvic and peritoneal surface. The condition can occur spontaneously, or iatrogenically after surgical seeding. We present the case of a 46-year-old woman who was incidentally diagnosed with DPL during a laparoscopic sling procedure for stress urinary incontinence. This patient had undergone a laparoscopic supracervical hysterectomy 9 years earlier for menorrhagia and uterine fibroids. During this procedure the uterine specimen had been removed with a laparoscopic morcellator. With the increase in laparoscopic hysterectomies and myomectomies, this case highlights the need for surgical diligence in removal of all morcellated fragments of the specimen. The patient should be made aware of the potential risks of this technique of tissue extraction.

S Afr J OG 2014;20(3):91-92. DOI:10.7196/SAJOG.874



Disseminated peritoneal leiomyomatosis (DPL) is a rare clinical condition where multiple smooth-muscle nodules or growths of various sizes implant on the peritoneal surface of the abdomen and pelvis. The appearance can mimic metastatic ovarian or peritoneal cancer.<sup>[1]</sup> This condition occurs mainly in premenopausal patients and has a benign course in the majority of cases, with less than 5% undergoing malignant transformation.<sup>[2]</sup> There is also evidence that the incidence of this condition is increasing as a result of iatrogenic seeding of the peritoneal cavity after morcellation of leiomyoma(s) at the time of minimally invasive surgical procedures.<sup>[3]</sup>

Less than 200 case reports have been described in the literature, with the majority of cases being diagnosed incidentally at the time of laparoscopy for other reasons.<sup>[4]</sup> This point also illustrates the benign and asymptomatic nature of this condition. Patients who are symptomatic will usually complain of chronic pelvic pressure or discomfort.

Seidman *et al.*<sup>[5]</sup> examined the pathology results of 1 096 hysterectomy specimens (from patients who underwent morcellation after hysterectomy or myomectomy), and a diagnosis of an unexpected leiomyoma variant was made in 1.2% of cases. This included one endometrial stromal sarcoma, one cellular leiomyoma, six atypical leiomyomas, three smooth-muscle tumours of uncertain malignant potential (STUMPs), and one leiomyosarcoma. There was a 64.3% prevalence of disseminated disease in these leiomyoma variants, indicating that leiomyoma variants increase the risk of disseminated disease. This study also suggested that uterine morcellation carries a risk of disseminating unexpected malignancy, with an apparent associated increase in mortality much higher than appreciated.<sup>[5]</sup>

Although asymptomatic DPL due to benign leiomyomas does not require treatment, excision of symptomatic nodules will have the obvious benefit of tissue diagnosis.<sup>[6]</sup>

## Case report

A 46-year-old woman (gravida 2, para 2) presented to a urogynaecology department complaining of stress urinary inconti-

nence. After history and physical examination confirmed the diagnosis, treatment options were discussed. The patient decided to proceed with a laparoscopic sling procedure. Her previous surgical history indicated that she had undergone a laparoscopic supracervical hysterectomy 9 years earlier for menorrhagia secondary to a fibroid uterus. The uterine specimen was removed with a laparoscopic morcellator using a 10 mm port in the right lower quadrant. Final pathology results at the time confirmed fragmented benign leiomyomas with the uterine specimen.

Pelvic examination under general anaesthesia at the time of laparoscopy revealed a normal-sized cervix with an adjacent mass.

Laparoscopy revealed a 1 cm fibroid-like structure noted upon placement of the right paraumbilical port (Fig. 1). A thorough examination of the rest of the pelvis and abdomen revealed a 3 cm ovoid structure over the left lateral pelvic sidewall close to the left round ligament (Fig. 2). Both fallopian tubes had fibroid-like growths within them (approximately 1 cm in diameter), and there was a larger 5 cm fibroid-like growth arising from the right adnexa (Fig. 3).

These lesions were excised with the aid of a CO<sub>2</sub> laser, bipolar forceps and laparoscopic scissors. There was no difficulty with the resection. The specimens were removed from the abdominal cavity in a laparoscopic bag after extending the umbilical incision from 10 to 20 mm. The specimens were then sent for pathological evaluation. Both ovaries were left *in situ*. After the fibroid-like masses had been excised, the laparoscopic sling procedure was commenced and completed. Final pathology results of resected specimens again identified fragments of benign leiomyoma, confirming the diagnosis of DPL.

## Discussion

Morcellation is an effective technique for removing myomas and uteri with laparoscopy, but carries a rare but significant risk of intraperitoneal seeding of specimen content, leading to DPL. This is of particular concern in rare cases where a tumour has been

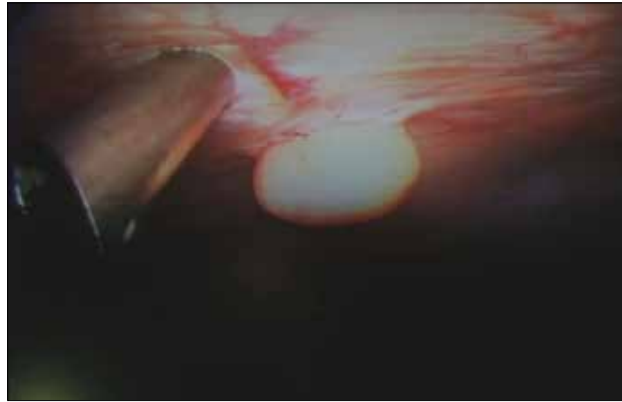


Fig. 1. Right paraumbilical port and 1 cm adjacent mass.

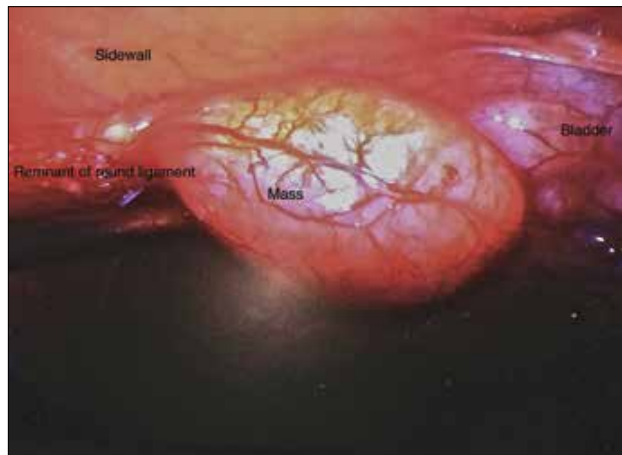


Fig. 2. Mass (3 cm) arising from left pelvic sidewall close to remnant of left round ligament.

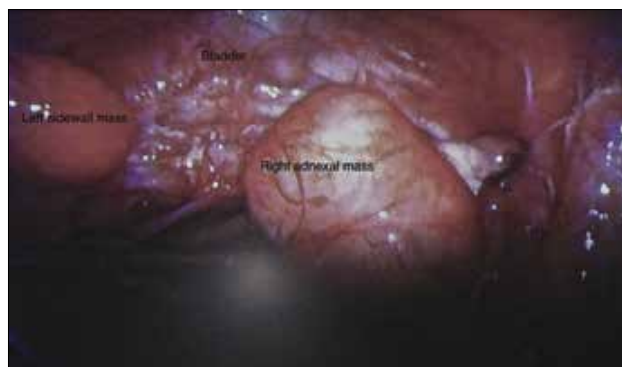


Fig. 3. Panoramic view of pelvis.

misclassified as benign preoperatively, but is an atypical leiomyoma variant or malignancy. The rate of misclassification varies between 0.09% and 1%.<sup>[5]</sup>

The recent controversy surrounding power morcellation of fibroids and uteri was sparked after an American physician developed

disseminated uterine sarcoma following laparoscopic hysterectomy for what was thought to be a benign fibroid uterus. The authors encountered their patient around the time the initial story broke. Since then, the US Food and Drug Administration have publicly discouraged the use of power morcellation. The American Association of Gynecologic Laparoscopists (AAGL)<sup>[7]</sup> and the American College of Obstetricians and Gynecologists (ACOG)<sup>[8]</sup> have reviewed this issue. They have concluded that all existing methods of tissue extraction carry risks and that all modalities of tissue extraction should remain available.

More recently, one of the largest health insurance companies in the USA has stopped covering this procedure, since 1 September 2014. Also, Johnson & Johnson, who have a large market share of power morcellator sales, ceased distribution in April 2014 and asked users worldwide to return the product.<sup>[9]</sup>

## Conclusion

This case highlights the importance of surgical diligence in removing all morcellated specimens at the time of laparoscopic supracervical hysterectomy and myomectomy.

Although the incidence of spontaneous DPL is rare, iatrogenic DPL secondary to morcellation will probably become more common than the current literature suggests.<sup>[3]</sup>

Prospective studies are needed to confirm this theory. Patients should be informed of the rare but potential risk when this technique of tissue extraction is used.

While the final word on the topic of power morcellation has not been spoken, physician experience and informed patient consent are of critical importance. Surgeons should also familiarise themselves with other techniques of tissue extraction, especially in cases where the diagnosis of benign leiomyomata is less certain.

**Consent.** Our patient provided written consent for publication of this case report.

1. Hardman WJ 3rd, Majmudar B. Leiomyomatosis peritonealis disseminata: Clinicopathologic analysis of five cases. *South Med J* 1996;89(3):291-294. [http://dx.doi.org/10.1097/00007611-199603000-00006]
2. Halama N, Grauling-Halama SA, Daboul I. Familial clustering of leiomyomatosis peritonealis disseminata: An unknown genetic syndrome? *BMC Gastroenterol* 2005;5:33.
3. Ordulu Z, Dal Cin P, Chong WW, et al. Disseminated peritoneal leiomyomatosis after laparoscopic supracervical hysterectomy with characteristic molecular cytogenetic findings of uterine leiomyoma. *Genes Chromosomes Cancer* 2010;49(12):1152-1160. [http://dx.doi.org/10.1002/gcc.20824]
4. Vaquero ME, Magrina JF, Leslie KO. Uterine smooth-muscle tumors with unusual growth patterns. *J Minim Invasive Gynecol* 2009;16(3):263-268. [http://dx.doi.org/10.1016/j.jmig.2009.01.013]
5. Seidman MA, Oduyebo T, Muto MG, Crum CP, Nucci MR, Quade BJ. Peritoneal dissemination complicating morcellation of uterine mesenchymal neoplasms. *PLoS One* 2012;7(11):1-8. [http://dx.doi.org/10.1371/journal.pone.0050058]
6. Takeda A, Mori M, Sakai K, Mitsui T, Nakamura H. Parasitic peritoneal leiomyomatosis diagnosed 6 years after laparoscopic myomectomy with electric tissue morcellation: Report of a case and review of the literature. *J Minim Invasive Gynecol* 2007;14(6):770-775. [http://dx.doi.org/10.1016/j.jmig.2007.07.004]
7. AAGL Tissue Extraction Task Force: Morcellation during uterine tissue extraction. May 2014. [http://www.aagl.org/wp-content/uploads/2014/05/Tissue\\_Extraction\\_TFR.pdf](http://www.aagl.org/wp-content/uploads/2014/05/Tissue_Extraction_TFR.pdf) (accessed 3 October 2014).
8. ACOG committee opinion: Power morcellation and occult malignancy in gynecologic surgery. May 2014. <http://www.acog.org/~media/Task%20Force%20and%20Work%20Group%20Reports/MorcellationSpecialReport.pdf> (accessed 3 October 2014).
9. Lee R. Johnson & Johnson recalls hysterectomy power morcellator that may spread cancer. *Tech Times*, 31 July 2014. <http://www.techtimes.com/articles/11735/20140731/johnson-johnson-recalls-hysterectomy-power-morcellator-that-may-spread-cancer.htm> (accessed 3 October 2014).